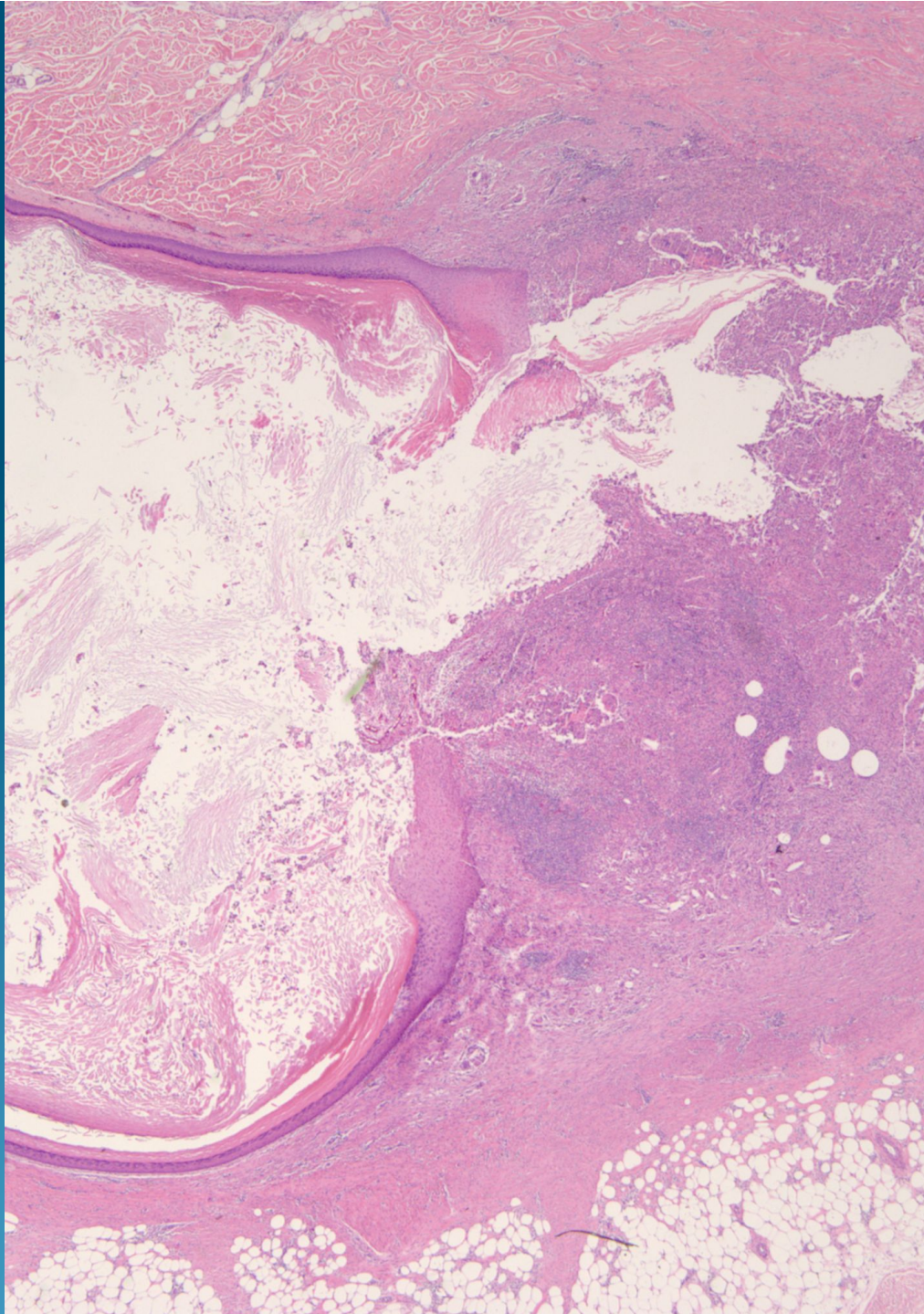
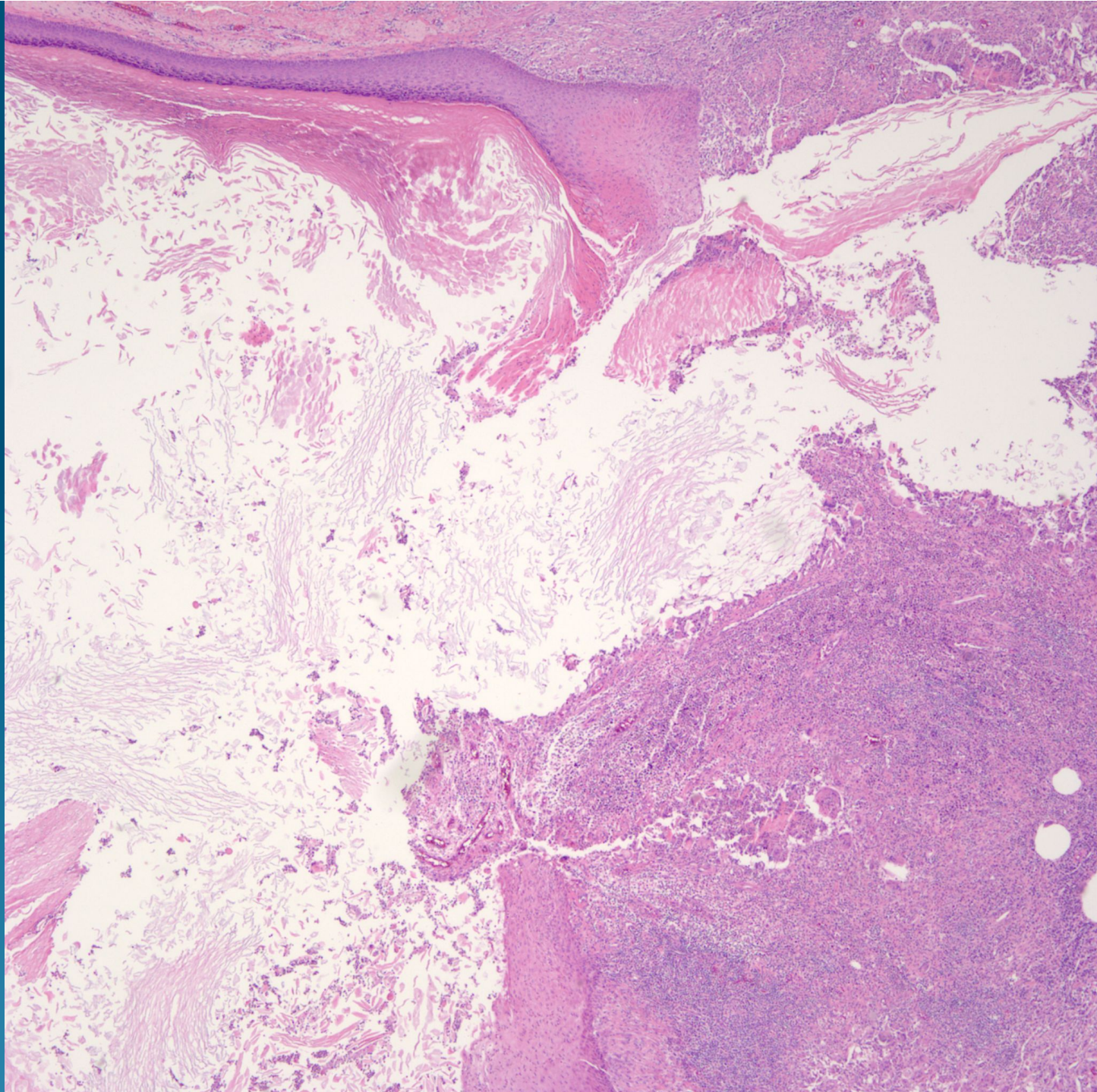
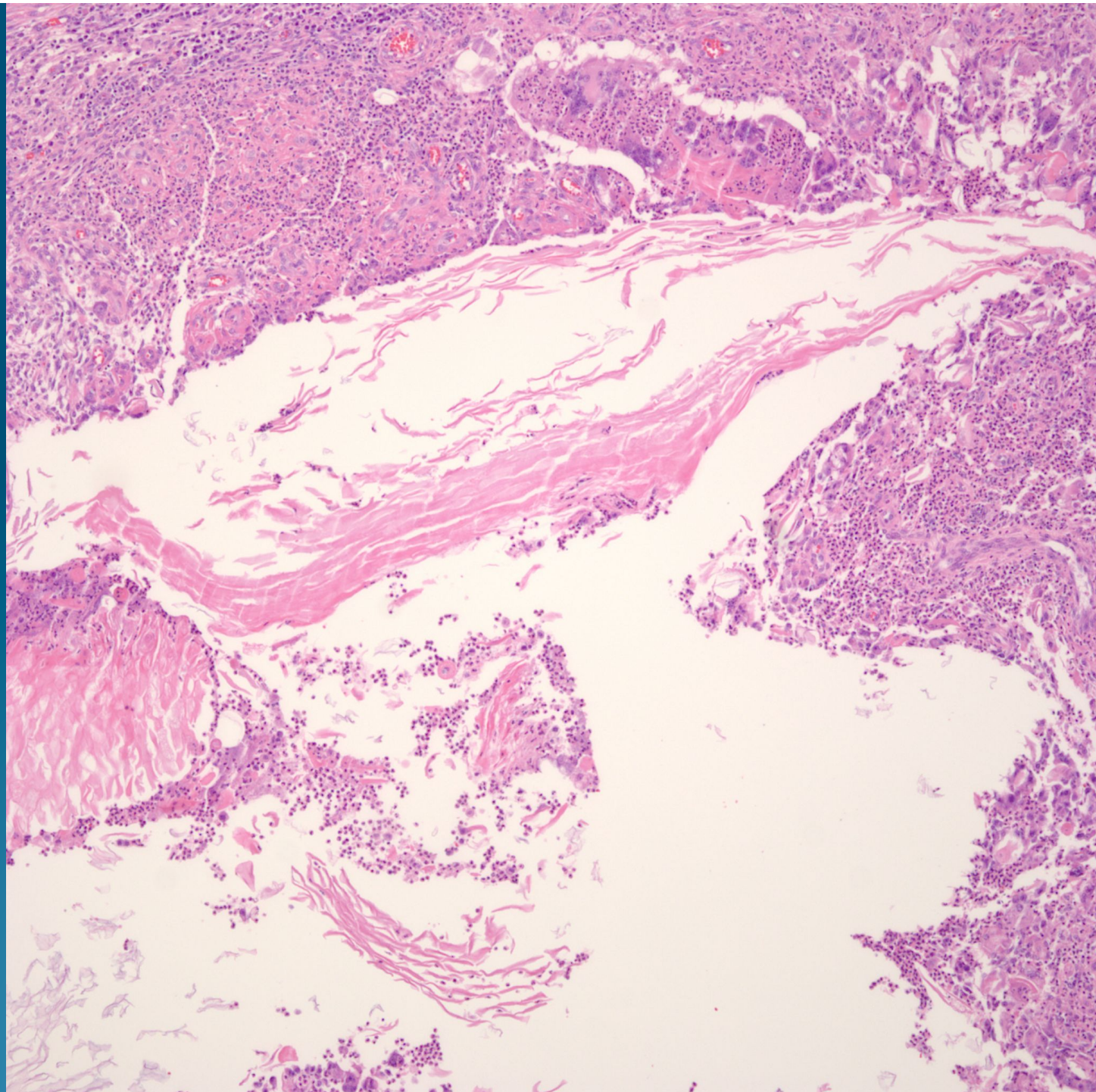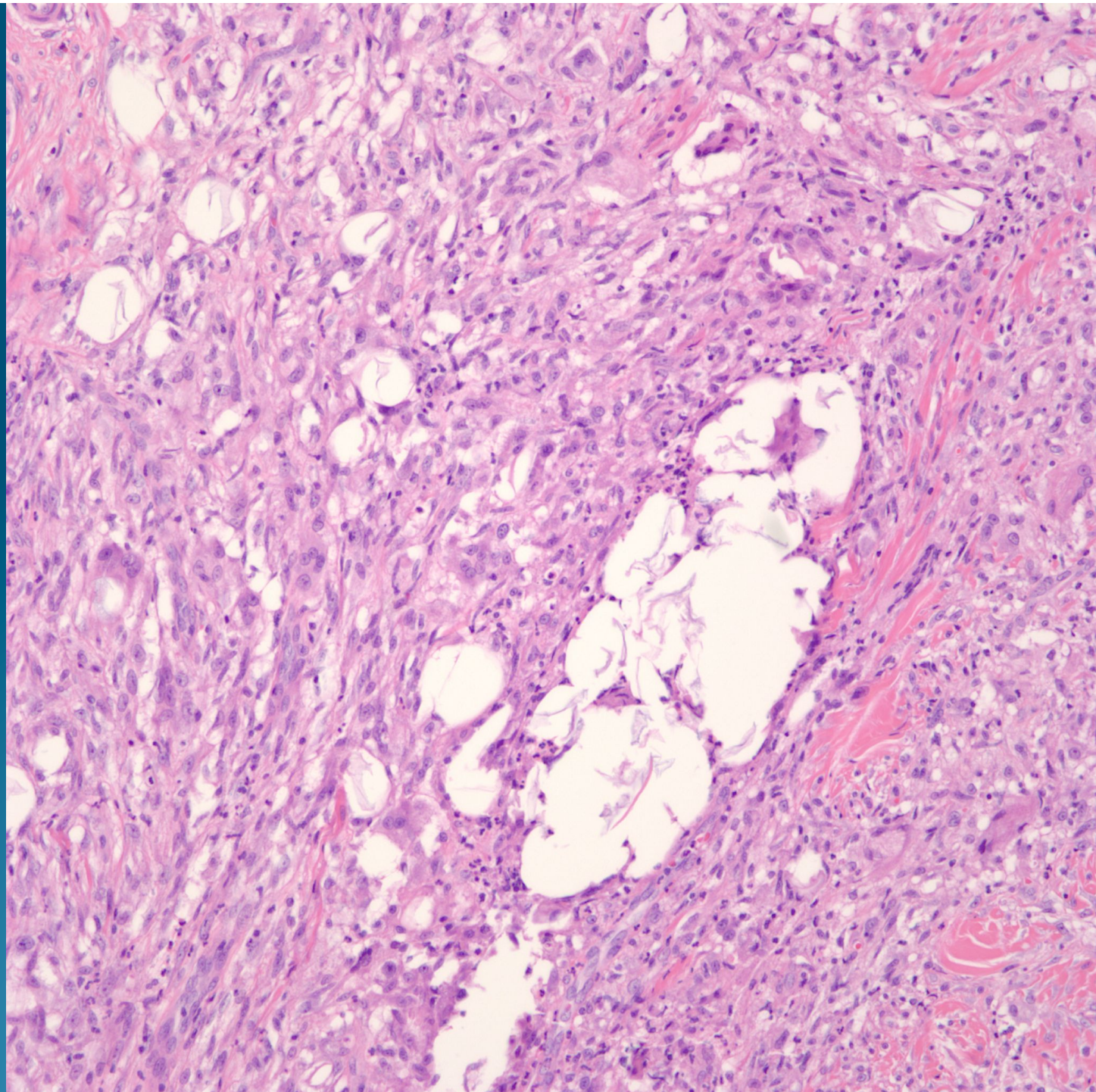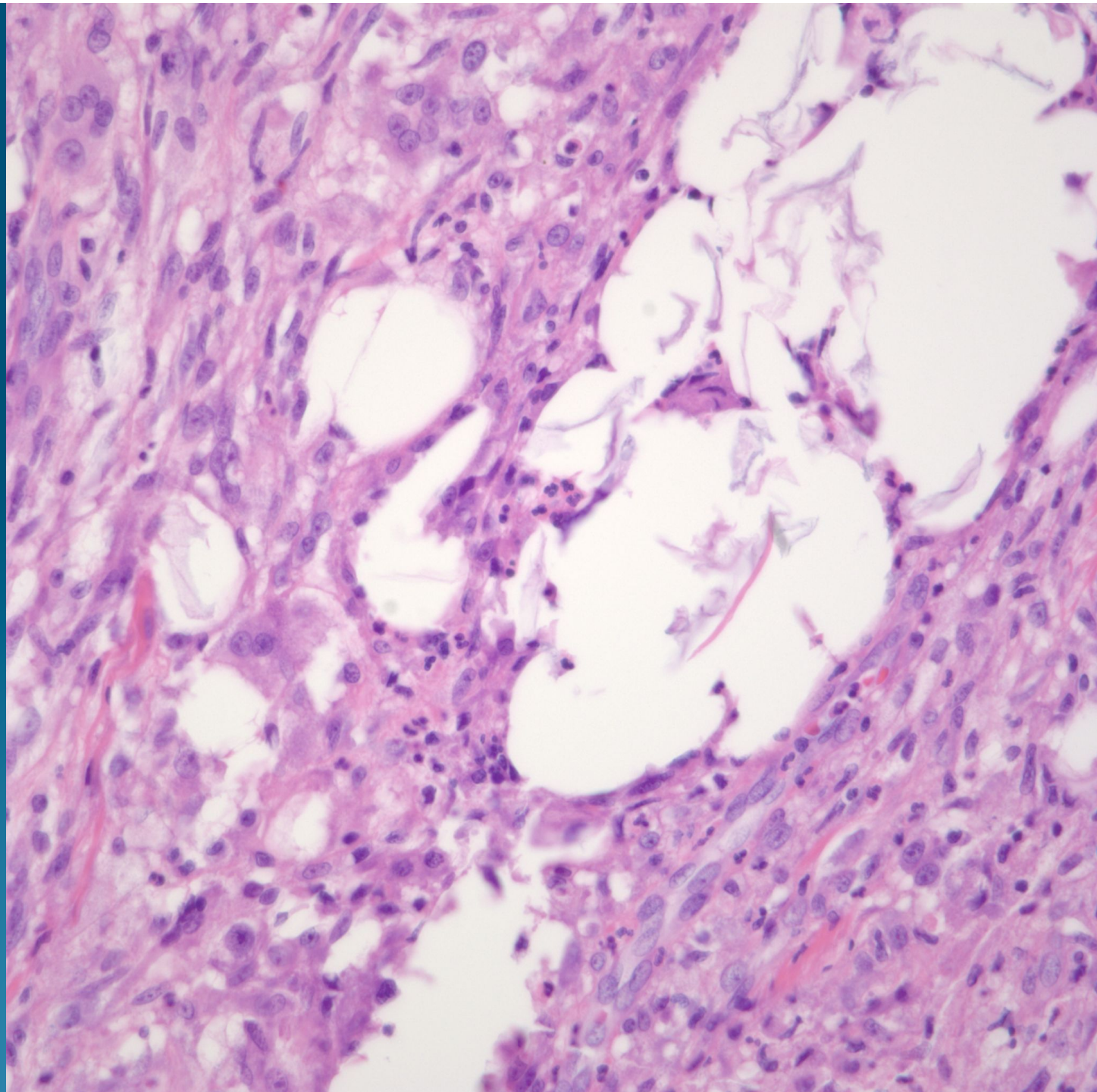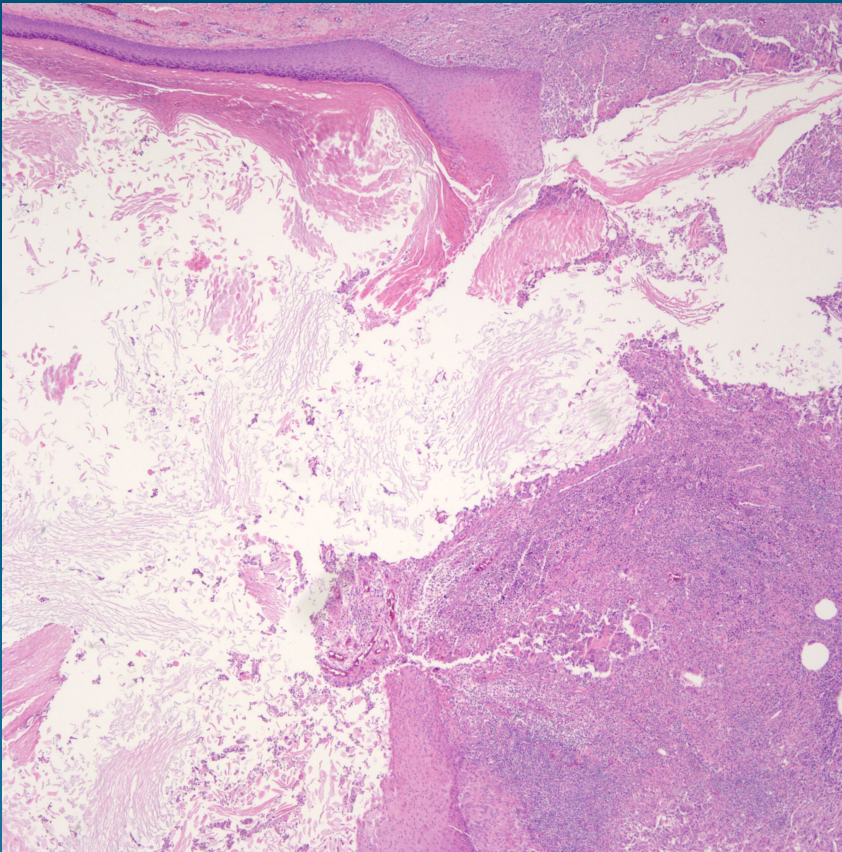
# What is the best diagnosis?

- A. Pilar cyst
- B. Epidermal inclusion cyst
- C. Nodular and Cystic Hidradenoma
- D. Pilomatricoma
- E. Cystic Warty Dyskeratoma

# Epidermal Inclusion Cyst with Rupture



# Pearls



- Squamous epithelial cyst which may show connection to overlying epidermis
- Squamous layer with keratohyaline granular layer
- Keratin in delicate layers
- Ruptured area with foreign body giant cells surrounding “cornflakes” of keratin